

Delayed Diagnosis of Digital Papillary Adenocarcinoma in the Finger Web Space: A Case Report with 3-Year Follow-Up

Talia Danze, BS; Angela Moore, MD

INTRODUCTION

- Rare sweat gland malignancy
- Typically occurs on volar digits
- Potential for local recurrence and metastasis
- Often misdiagnosed due to benign appearance

CASE PRESENTATION

- Patient: 58-year-old Black female
- Location: Left middle finger web space
- History: 14-year duration, growth over last 2 years
- Misdiagnosis: Keloid (family history)
- Symptoms: Intermittent pain and itching

DIAGNOSTIC WORKUP

- Biopsy: Infiltrating carcinoma with rare pseudopapillary structures
- IHC Markers:
 - o CK-pan, CK7, EMA, S100 (+)
 - o SMA in myoepithelial cells
- No perineural or lymphovascular invasion

TREATMENT

- Initial Excision: 1 cm margins → positive margins
- Second Surgery: Wider local excision with additional 1 cm
- Defect: 4 x 4 cm to tendon
- Imaging: No bone or nodal involvement
- Decision: Amputation avoided

KEY TAKEAWAYS

- Always biopsy enlarging or chronic lesions
- DPA may present in non-volar locations
- Wide excision can be curative without amputation
- Close follow-up is essential

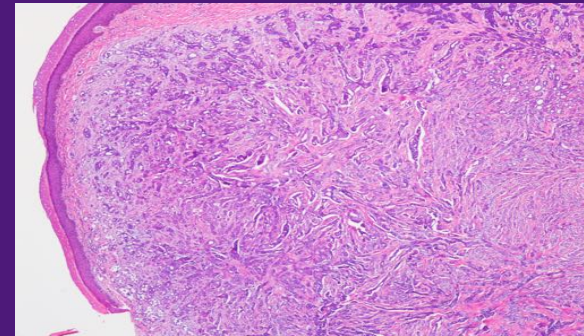


Figure 1: 40X H&E

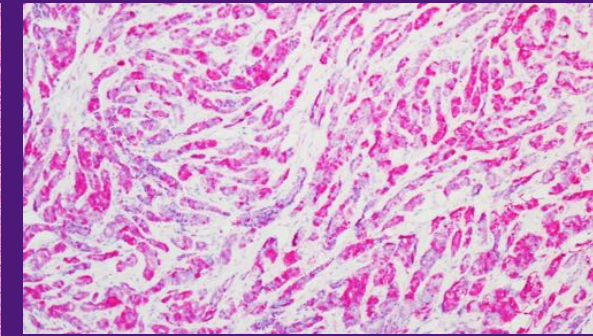


Figure 2: S100 100X

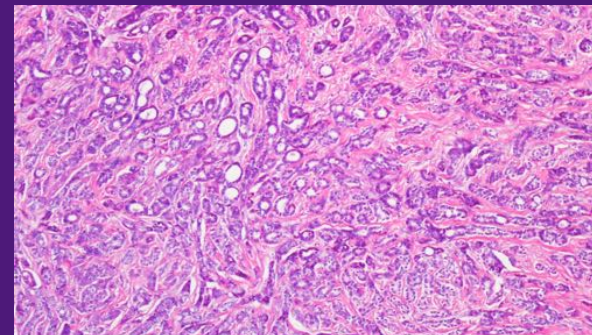


Figure 3: 100X H&E

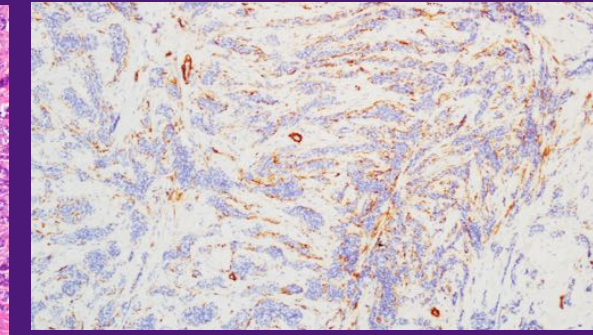


Figure 4: SMA 100X

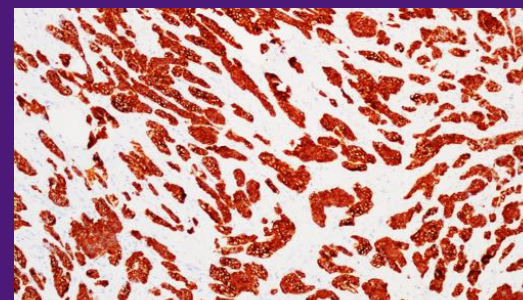


Figure 5: CK7 100X

OUTCOMES

- Follow-Up: 3 years
- Status: No evidence of recurrence or metastasis
- Surveillance: Ongoing

DISCUSSION

- DPA often mimics benign lesions
- Rare in web spaces → risk of misdiagnosis
- Long-standing lesion with favorable outcome after wide excision
- Highlights the importance of early biopsy in persistent nodules

REFERENCES

1. Hsu, H. C., Ho, C. Y., Chen, C. H., Yang, C. H., Hong, H. S., & Chuang, Y. H. (2010). Aggressive digital papillary adenocarcinoma: A review. *Clinical and Experimental Dermatology*, 35(2), 113–119.
2. Andrew, K., van Bodegraven, B., Vernon, S., Balogun, M., Craig, P., Rajan, N., Venables, Z. C., & Tso, S. (2024). National epidemiology of digital papillary adenocarcinoma in England 2013–2020: A population-based registry study. *Clinical and Experimental Dermatology*, 49(11), 1389–1395.
3. Dhillon, P., Powell, B., & Mehdi, S. (2020). Aggressive digital papillary adenocarcinoma and sentinel node biopsy: A case report and literature review. *JPRAS Open*, 24, 43–46.
4. Guo, E. W., Yoon, A. P., & Chung, K. C. (2022). Wide local excision with sentinel lymph node biopsy for digital papillary adenocarcinoma: A case report. *Journal of Hand Surgery (Asian-Pacific Volume)*, 27(6), 1048–1052.
5. Feldmeyer, L., Prieto, V. G., Ivan, D., Nagarajan, P., Tetzlaff, M. T., Curry, J. L., Bell, D., Moon, B. S., Torres-Cabala, C. A., & Aung, P. P. (2016). Role of radiotherapy in aggressive digital papillary adenocarcinoma. *Annals of Clinical and Laboratory Science*, 46(2), 222–224.
6. Knackstedt, R. W., Knackstedt, T. J., Findley, A. B., Piliang, M., Jellinek, N. J., Bernard, S. L., & Vidimos, A. (2017). Aggressive digital papillary adenocarcinoma: Treatment with Mohs micrographic surgery and an update of the literature. *International Journal of Dermatology*, 56(10), 1061–1064.
7. Gupta, J., Gulati, A., Gupta, M., & Gupta, A. (2019). Aggressive digital papillary adenocarcinoma at atypical site. *Clinical Medicine Insights: Case Reports*, 12, 1179547619828723. <https://doi.org/10.1177/1179547619828723>
8. Dege, T., Rütten, A., Goebeler, M., & Kneitz, H. (2024). Digital papillary adenocarcinoma is HPV-42-associated and BRAF V600E negative: Perspectives for diagnostic practice. *Dermatopathology (Basel)*, 11(4), 348–353.
9. Chen, E. L. A., & Nijhawan, R. I. (2021). Aggressive digital papillary adenocarcinoma initially misdiagnosed as basal cell carcinoma. *Dermatologic Surgery*, 47(1), 137–139.
10. Haynes, D., Thompson, C., Leitenberger, J., & Vetto, J. (2017). Mohs micrographic surgery as a digit-sparing treatment for aggressive digital papillary adenocarcinoma. *Dermatologic Surgery*, 43(12), 1487–1489.