

# Rare case presentation of dozens of facial hidrocystomas confirmed by histopathology

Sydney Kenney, BS, Jacqueline Cochran, MD

Department of Dermatology, Kaiser Permanente, and Kaiser Permanente School of Medicine, Pasadena, CA



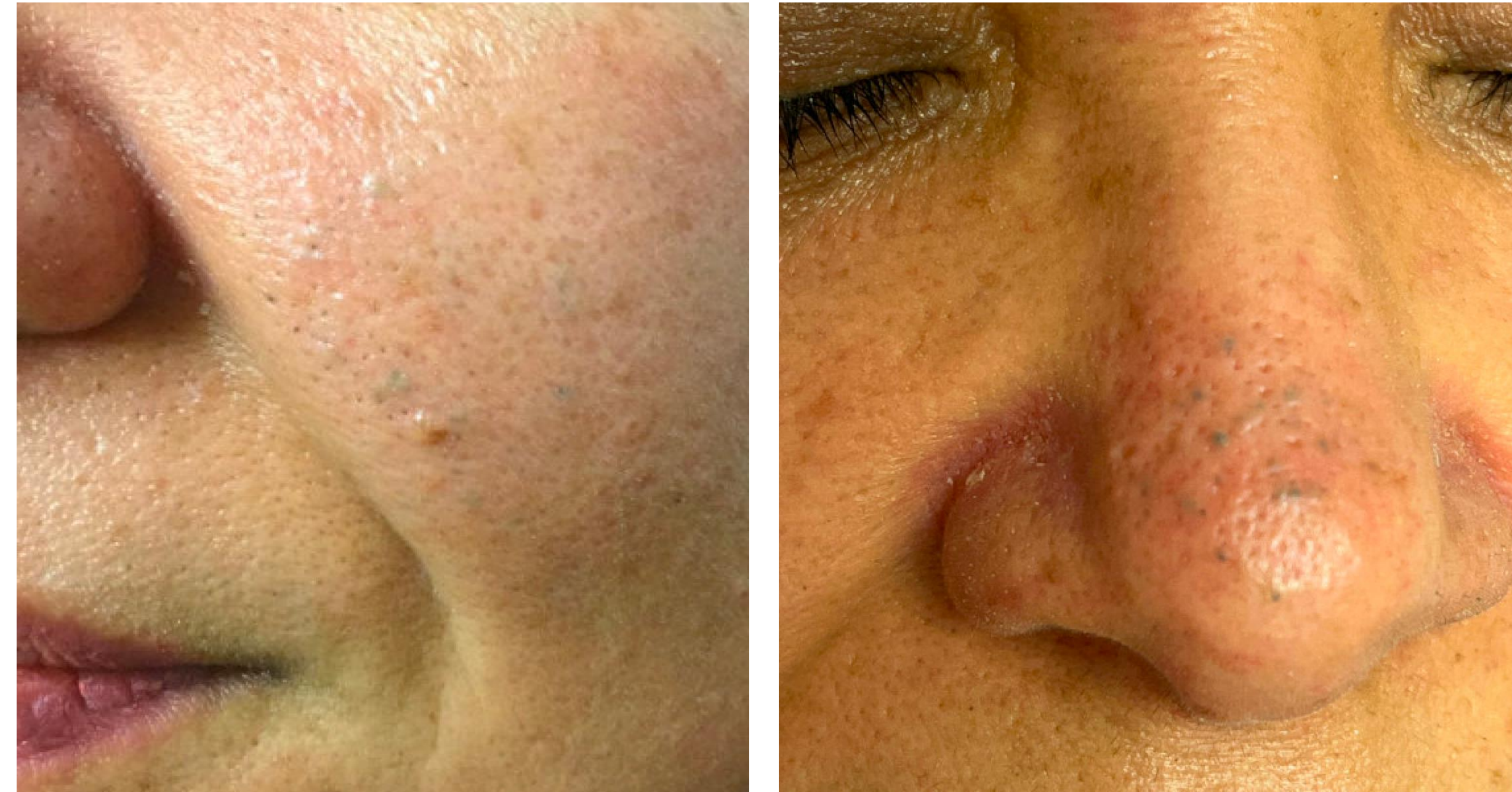## Background

- Hidrocystomas are rare, benign cystic tumors of either eccrine or apocrine gland epithelium. The eccrine form may appear as solitary or multiple adenomatous papules or nodules, and are commonly found periocularly, in the scalp, and around the neck.
- These lesions have size ranges from 1-15 mm, the smaller lesions are typically of eccrine origin, and they are translucent with palpable mobility. These characteristics aid in quick recognition and diagnosis of hidrocystomas.
- Many underlying conditions such as Schopf-Schulz-Passarge and Goltz-Gorlin Syndromes, as well as Graves disease and Carney Complex may present with hidrocystomas or similar eccrine tumors. Hyperhidrosis is also a documented risk factor.

## Case Presentation

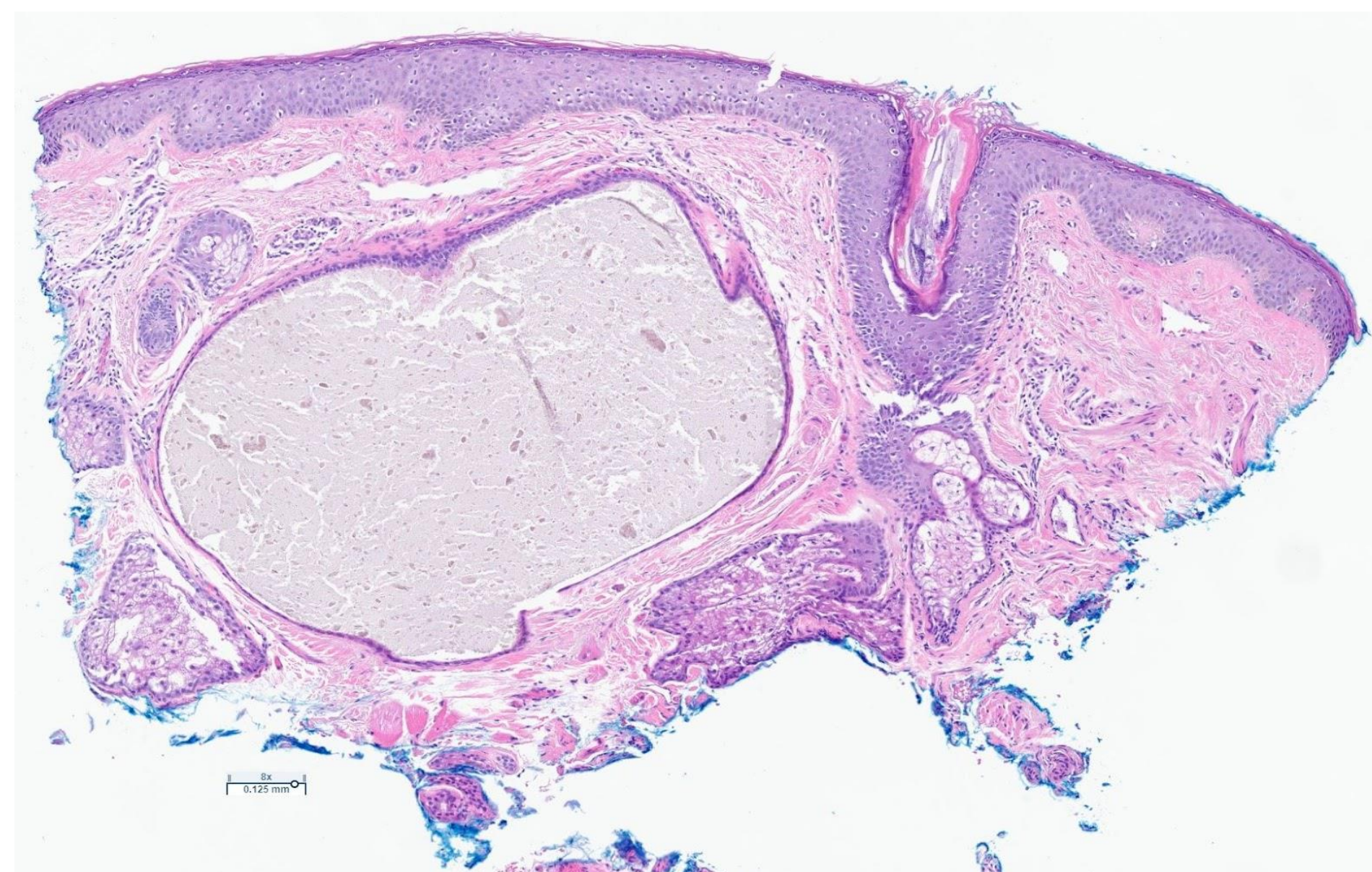
- A 52-year-old woman with a past medical history of hyperlipidemia and psoriasis presented to Dermatology outpatient clinic regarding abnormal discoloration of the tip of her nose, chin, and cheeks for nearly 6 years.
- The papules were not itchy, did not expel fluid, exudate, or oil when pressure was applied, and had not increased in size. They did not worsen during hot weather. However, they had increased in number and the hue intensity over time despite laser, tretinoin, and topical exfoliative therapies.
- On dermatologic evaluation, multiple blue-black macules were noted across the nose and bilateral cheeks in the absence of erythema or crusting. The largest macule measured roughly 2mm and the smallest was approximately 0.5mm in diameter (Figure 1).
- A punch biopsy of a solitary lesion on the chin was taken for histopathologic diagnosis (Figure 2).

## Images



**Figure 1 (Above): Patient presentation photos**

Over two dozen blue-black perifollicular macules were present across the cheeks bilaterally (left) and across the bridge of the nose (right). Additionally, several lesions were scattered across the chin. Initial differential diagnoses for such blue-black perifollicular macule included blue nevi, exogenous or drug-induced hyperpigmentation (such as argyria), dilated pore of winer/comedone, and hidrocystoma.



**Figure 2 (Left): Histology of chin biopsy, H&E Stain, 10X**

Histopathologic examination revealed a large unilocular cystic space within the dermis filled with gelatinous material, containing a thin and fibrous pseudocapsule. This evaluation is consistent with eccrine hidrocystoma histology and thus unconvincingly confirmed the diagnosis. Although, considerably inconsistent with the clinical presentation.

## Discussion

- In this patient, we observed a puzzling presentation of dozens of scattered, flat, blueish-black hidrocystomas on the chin, nose, and cheeks in absence of common features such as translucency, mobility, or papule appearance.
- Aside from psoriasis, she had no other conditions or aforementioned factors with documented associations in developing hidrocystomas. Additionally, these hidrocystomas appeared in a region containing sparse glands, as opposed to the more common locations such as the axilla, periorbital, scalp, and neck.
- She experienced resolve with the chin solitary hidrocystoma with no evidence of recurrence at the six-month follow-up visit. However, due to the complex and numerous presentations of these hidrocystomas, excisional biopsies are not a reasonable therapeutic option.
- Alternative non-surgical options suggested in literature include laser therapy, such as CO2 or pulsed dye laser treatment, and once-daily application of topical atropine ointment 1% or scopolamine cream 0.01%.

## References

1. James, W. D., Elston, D. M., Treat, J. R., Rosenbach, M. A., & Neuhaus, I. M. (2020). Epidermal nevi, neoplasms, and cysts. In *Andrews' Diseases of the Skin: Clinical Dermatology* (13th ed., pp. 636-685). Elsevier.
2. Ogawa, T., Imabayashi, H., Hashimoto, K., Matsumoto, H., & Tashiro, T. (2023). Paraganglioma, nonchromaffin. In *StatPearls*. StatPearls Publishing.
3. Rappazzo, K. C., & Cohen, P. R. (2016). Pigmented hidrocystoma of nasal epithelium (PHONE): report of a man with a pigmented hidrocystoma of his nose and literature review. *Dermatology online journal*, 22(5), 13030/qt9c50d26x.
4. Sarabi, K., & Khachemoune, A. (2006). Hidrocystomas—a brief review. *MedGenMed: Medscape general medicine*, 8(3), 57.

## Disclosures

Nothing To Disclose –The authors of this abstract have indicated that they have no conflicts of interest that relate to the content of this abstract.