Human Botfly Infestation: Furuncular Myiasis

Rachel Rhee, BA[1] Christina Borchers, MD,[1] Samia Borchers, MD,[2] Gregory Maupin, MD [3], Jeffrey Weinstein, MD [4]

Wright State University Boonshoft School of Medicine, Dayton, OH[1], Samia W. Borchers Dermatology, Dayton, OH[2], Maupin Johnson, Dayton, OH[3], Acute Care Consultants, Dayton, OH[4]

WRIGHT STATE UNIVERSITY

Background & Objective

The *Dermatobia hominis* is one of many species of botflies whose larvae is parasitic to humans and is uniquely indigenous to Central and South America. The larvae of the human botfly gains nutrients to survive by feeding underneath mammal skin. The infestation of any fly larvae inside the body is known as myiasis.

As a consequence, within 24 hours, small 2-3 mm painful, erythematous, draining, and purulent papules with a classical air-pore can develop as the initial cutaneous sign. At first, the lesions resemble that of an insect bite, but over time they enlarge to 10-35 mm in diameter with a surrounding area of induration. The most common areas where the larvae are cutaneously deposited include the upper and lower extremities, scalp, and back. Of note, systemic symptoms are not typically described, but more mild constitutional findings such as malaise, insomnia, and lethargy have been noted in literature.

Case Presentation

Our case involves a 38-year-old gentleman who came in for an inflamed cystic 15 mm plaque on his left upper lip skin. He was seen two days prior at an urgent care and was given an intramuscular antibiotic, cephalexin, and ibuprofen. Two days later he presented to dermatology and was treated with intralesional triamcinolone 5 mg/cc. After 10 days, the patient did his own online research on botflies since he was in Belize 7 weeks prior and recalled hearing about botflies. He applied Vaseline to the area and the botfly larva poked out its head for air and confirmed his suspicion. A second appointment was made with dermatology. Under local anesthesia, numerous attempts to grasp the larva after Vaseline smothering were unsuccessful as it would burrow back inside a tunnel. The patient was referred to an infectious disease specialist who based on the patient's history, determined that he developed a furuncular myiasis from the larval form of *D. hominis*. The infectious disease specialist put him on Augmentin 875 mg BID and referred the patient to a plastic surgeon for surgical extraction.

Methods

The plastic surgeon injected the larva with local lidocaine with epinephrine and the high pressure of the injection actually caused the larva to back out on it's own. The area was then opened up, debrided, and packed open with Iodoform gauze. The extraction site healed without complications and the patient was maintained on Augmentin 875 mg per recommendation by the infectious disease specialist.

Figures

Figure 1. *Dermatobia hominis* larva upon extraction

Figure 2. Furuncle prior to the extraction of the larvae. Central white speck is the tail tip seen in figure 1.

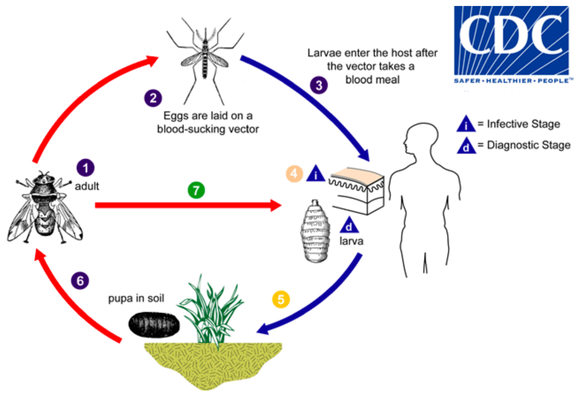

Figure 3. Life cycle of the botfly

Results

The patient developed furuncular myiasis due to a botfly larva that is common in Central America. The larva was successfully extracted under high pressure of lidocaine injection and subsequently sent to pathology for identification and analysis. Pathology identified the object as a human botfly larva.

Conclusion

While myiasis caused by *D. hominis* is rarely seen in the United States, it is more common among residents and visitors of Central and South America. The female botfly lays her eggs onto an intermediate host, such as a mosquito, which serves as a vector onto the human skin when it feeds. The heat of the skin causes the eggs to hatch into larvae, which breathe through a central punctum. This type of myiasis lives in healthy tissue, not necrotic tissue.

Treatment is removal of the worm, but in this form of myiasis, it required incision and debridement under local anesthetic. Attempts to surgically extract the larva were limited due to the retraction of the head, and Vaseline attempts to suffocate the larva were unsuccessful due to the size of the central air-pore. Ultimately, the patient underwent injection with lidocaine with epinephrine which caused the larva to become expelled under the high pressure.

Because of the unspecific symptoms and low incidence of *D. hominis* in the United States, misdiagnosis or delayed treatment of the lesion happens frequently as our patient experienced. High clinical suspicion is needed to diagnose these types of lesions. This case is also important to further classify the cutaneous manifestations of human botfly infestations and in the prevention of secondary bacterial infections or granuloma development in patients post-extraction.

References

1. Hill S, Connelly R. Human botfly - Dermatobia hominis. Entnemdept.ufl.edu. http://entnemdept.ufl.edu/creatures/misc/flies/human_bot_fly.htm. Published 2008. Accessed August 21, 2020.
2. Parasites - Myiasis. In: *CDC*. ; 2013. https://www.cdc.gov/parasites/myiasis/biology.html. Accessed August 21, 2020.
3. Shenouda M, Enten G, Nguyen T, Mangar D, Camporesi E. Human botfly: a case report and overview of differential diagnosis. *J Investig Med High Impact Case Rep*. 2018 Jan-Dec; 6. doi: 10.1177/2324709618801692

Disclosures: The author(s) have no financial relationships to disclose.