# Hidradenitis Suppurativa

Jennifer Hsiao, MD
USC Dermatology

## Disclosures

- I am on the board of directors for the Hidradenitis Suppurativa Foundation
- I have served as an advisor for Novartis, UCB, and Boehringer Ingelheim and as a speaker and advisor for AbbVie
- Will discuss off-label uses of medications

# Outline

- Background information
- Clinical features
- Treatments
  - Medical therapeutics
  - Procedural management
  - Emerging therapies
- Management Tips
- Comorbidities and Complications

# Epidemiology

- Estimated prevalence of HS varies from 0.05% to 4.1%
- Recent retrospective analysis of a heterogenous populations-based sample of more than 48 million patients across the United States
  - Overall HS prevalence found to be 0.1%
  - Prevalence in women more than twice that of men
  - Prevalence of HS highest among patients aged 30 to 39 years
  - HS prevalence among African American and biracial patients were more than 3-fold and 2-fold greater than that among white patients

Saunte et al. JAMA. 2017
Garg et al. JAMA Dermatol. 2017

# Scope of the Problem

- A recent multicenter survey (N=1,299 across 27 institutions in 14 countries) found that mean delay in diagnosis was **10.2 years**
- Most patients visited a physician at least **5x** prior to receiving a diagnosis
- For HS-related symptoms, 18.3% (n=238) of participants reported visiting the emergency department >5 times, and 12.5% (n=163) of participants reported having been hospitalized >5 times
- Access to dermatology was rated as difficult by 37% (n=481)
- 14.5% (n=189) of participants reported being disabled and unable to work due to HS

Garg et al. J Am Acad Dermatol. 2019

# Pathogenesis

- **Immune Dysregulation**
  - Increased TNF-α, IL-1, IL-10, IL-17, IL-12, IL-23, IL-22, IL-20, IL-36 found in lesional HS skin compared to healthy control skin
  - Therapeutic response to anti-TNF-α, anti-IL-1, anti-IL-17, and anti-IL-12/23 agents in some studies
- **Hormones**

Kromann et al. Br J Dermatol. 2014
Kelly et al. Int J Dermatol. 2014
Vossen et al. J Am Acad Dermatol. 2017
Frew et al. J Invest Dermatol. 2021

# Pathogenesis

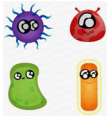

- **Follicular Occlusion**: HS is an inflammatory disorder originating from the hair follicle
  - Follicular occlusion leads to perifollicular cyst development and then rupture of cyst contents (including bacteria) into the dermis
- **Microbiome**: Role of bacteria remains controversial
  - Bacterial biofilms have been found in acute HS lesions and HS sinus tracts
- **Genetics**: There is a familial form of HS with AD inheritance
  - Mutations in genes that make up the gamma-secretase protein complex have been found in patients with familial HS

Ring et al. Exp Dermatol. 2015
Hoffman et al. Semin Cutan Med Surg. 2017
Ring et al. JAMA Dermatol. 2017
Okoye et al. Br J Dermatol. 2017


Shih et al. Cutis. 2021

# Clinical Presentation

Criteria for diagnosis:

1. Typical lesions present: nodule, abscess, sinus tract, scar
2. Typical locations involved: axillae, groin, perineum, buttocks, infra- and intermammary folds
3. History of chronicity and recurrence

Van der Zee et al. J Am Acad Dermatol. 2015

# Hurley Stage 1

## Hurley Stage 2

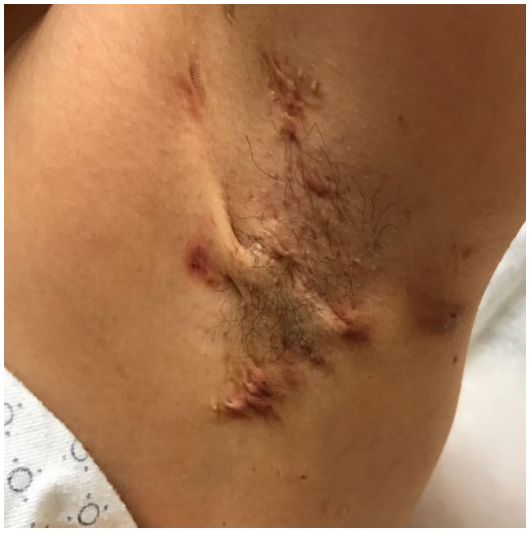

## Hurley Stage 3

# Other Scoring Systems

- **Hidradenitis Suppurativa Clinical Response** (HiSCR)
  - At least a 50% reduction from baseline in the total abscess and inflammatory-nodule count, with no increase in the abscess or draining-fistula count
- **Sartorius score**
  - Incorporates the involved anatomic regions, number and types of lesions, distance between lesions, and the presence of normal skin in between lesions
- **Hidradenitis Suppurativa - Physician Global Assessment** (HS - PGA)
  - 6-point score ranging from clear to very severe, based on number of inflammatory and non-inflammatory nodules, abscesses, and draining fistulas
- **International Hidradenitis Suppurativa Severity Score System** (IHS4)
  - Nodules, abscesses, draining tunnels are scored
- **Hidradenitis Suppurativa Severity Index** (HSSI)
  - Incorporates number of anatomic sites and body surface area involved, number of lesions, pain severity (determined through a visual analogue scale), and drainage

# North American Guidelines for HS

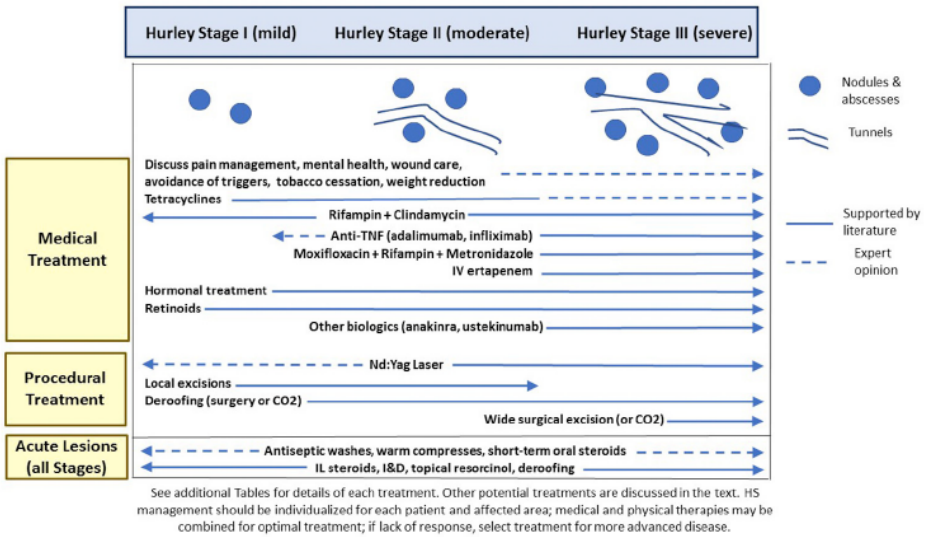


See additional Tables for details of each treatment. Other potential treatments are discussed in the text. HS management should be individualized for each patient and affected area; medical and physical therapies may be combined for optimal treatment; if lack of response, select treatment for more advanced disease.

Alikhan et al. J Am Acad Dermatol. 2019

# Lifestyle Modifications

- Smoking cessation
- Weight loss
- Avoid tight fitting clothing

# **Medical Therapeutics**

## Topical Treatments

- Clindamycin 1% topical (gel, lotion, or solution)
- Dapsone 5% gel
- Gentamicin 0.1% topical
- Metronidazole 0.75% topical

- Can combine with antiseptic washes:
  - Chlorhexidine (hibiclens) wash
  - Benzoyl peroxide wash

Scheinfeld. Dermatol Online J. 2013
Pascual et al. J Am Acad Dermatol. 2017
Boer et al. Clin Exp Dermatol. 2010

## Topical Resorcinol

- Resorcinol is a phenol derivate, used in dermatology mainly because of its keratolytic properties, though it also has effects on controlling inflammation as well

- Peeling effect starts at concentrations of 10%

- **Study of 32 patients with Hurley Stage I and II**: Resorcinol 15% topical BID for 30 days led to reductions in pain and size (a significant difference already seen by day 7)

- No pregnancy category assigned

Pascual et al. J Am Acad Dermatol. 2017
Boer et al. Clin Exp Dermatol. 2010

## Systemic Antibiotics - Monotherapy**

- Doxycycline 100mg PO BID or Minocycline 100mg PO BID (or extended release minocycline at weight adjusted dose once a day) for 8-12 weeks
- Dapsone 50mg to 200mg PO daily
  - Check CBC, CMP, G6PD

**Appropriate for Hurley Stage I and II patients

Jemec et al. J Am Acad Dermatol. 1998
Kaur et al. J Dermatolog Treat. 2006
Yazdanyar et al. Dermatology. 2011

## Systemic Antibiotics - Combined Therapy

- Clindamycin 300mg PO BID and Rifampin 300mg PO BID for 10-12 weeks
- Rifampin (10mg/kg/day) + moxifloxacin 400mg/day + metronidazole 500mg TID for 12 weeks (metronidazole for first six weeks only)
  - Can also trial rifampin + levofloxacin + metronidazole
- For severe HS patients, can start with induction treatment with IV ertapenem (1g daily) for 6 weeks before consolidation treatment with combination oral antibiotics
  - Induction treatment with IV ceftriaxone (1g daily) + oral metronidazole (500mg TID) for 3-4 weeks has also been reported

Gener et al. Dermatology. 2009
Join-Lambert et al. Dermatology. 2011
Join-Lambert et al. J Antimicrob Chemother. 2016

# Oral Retinoids

- Acitretin 0.5mg/kg/day may be beneficial, although given side effects, dose may be limited to 25mg daily

Matusiak et al. Br J Dermatol. 2014

# Oral Retinoids

- Isotretinoin – mixed results in the literature
  - Study of 68 HS patients found that 23.5% had clearance *(treatment was more successful in milder forms of HS)*[1]
  - A retrospective study of 358 patients found that of 88 patients who had previously been treated with oral isotretinoin, only 14 patients (16%) reported an improvement[2]
  - A retrospective chart review of 25 patients on isotretinoin 0.45mg/kg/day for average of 6.8 months found that 32% showed PR and 36% showed CR *(only seen in Hurley stage I and II patients)* [3]

1. Boer et al. J Am Acad Dermatol. 1999;
2. Soria et al. Dermatology. 2009;
3. Huang et al. Dermatology. 2017

# Apremilast

- Phosphodiesterase 4 inhibitor
- Dosing: 30mg PO BID
- 2019 RCT: 13/20 (65%) patients with mild-to-moderate HS achieved HiSCR30 at weeks 16 and 24, similar proportion achieved HiSCR50
- 2019 RCT: 8/15 (53%) patients with moderate HS achieved HiSCR, none of the 5 patients in placebo group achieved HiSCR, at 16 weeks
- 2017 Case series of 9 patients (Hurley stage II-III), 3 dropped out, 5/6 improved

Kerdel et al. J Drugs Dermatol. 2019
Vossen et al. J Am Acad Dermatol. 2019
Weber et al. J Am Acad Dermatol. 2017

# Hormonal Therapy

**For women**:

- Spironolactone 50 to 150mg daily
- OCP *(with increased estrogen and with anti-androgenic progestin, like drospirenone)*

**For men (and sometimes women)**:

- Finasteride 5 to 10mg daily

**For both**:

- Metformin 500mg to 1500mg daily *(especially in patients who are obese or who have pre-diabetes or diabetes)*

Scheinfeld. Dermatol Online J. 2013
Verdolini et al. J Eur Acad Dermatol Venereol. 2013; Jennings et al. J Dermatolog Treat. 2019

# Biologics

**Most evidence behind**:

- Adalimumab *(FDA approved)*
- Infliximab

**Other biologics to consider**:

- Secukinumab
- Ustekinumab
- Anakinra
- IL-23 inhibitor (Guselkumab, Risankizumab, Tildrakizumab)

# Adalimumab

- Fully human monoclonal antibody against TNF-alpha
- Dosing schedule
  - Day 1: 160mg SC x 1
  - Day 15: 80mg SC x 1
  - Day 29: 40mg SC weekly **or 80mg SC q2 weeks**


Kimball et al. NEJM. 2016

The NEW ENGLAND JOURNAL of MEDICINE

ORIGINAL ARTICLE

Two Phase 3 Trials of Adalimumab for Hidradenitis Suppurativa

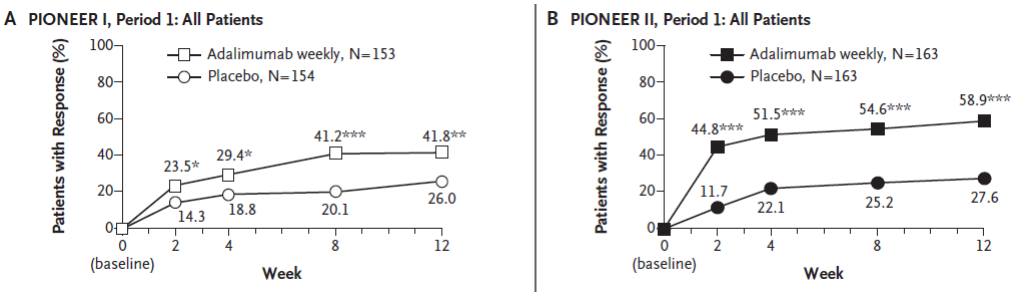


Kimball et al. NEJM. 2016

# Infliximab

- Chimeric (mouse/human) monoclonal antibody against TNF-alpha
- Dosing: 7.5-10mg/kg infusion at weeks 0, 2, and 6, then q4-8 weeks
- Can consider adding low dose methotrexate to prevent anti-drug antibodies (ADA)

Ghias et al. J Am Acad Dermatol. 2019; Oskardmay et al. J Am Acad Dermatol. 2019
Grant et al. J Am Acad Dermatol. 2010; Lesage et al. Eur J Dermatol. 2012; Paradela et al. J Dermatol Treat. 2012

# Secukinumab

- Human monoclonal antibody against IL-17A
- Dosing: 300mg SQ once weekly for 5 weeks, then q2 or q4 weeks
- Open label study (patients and investigators not blinded to treatment)
  - 20 patients with moderate to severe HS (9 on q4 weeks and 11 on q2 week dosing)
  - 70% (14/20) achieved HiSCR by week 24 using last-observation-carried forward to handle missing values (n=13 patients completed the study)
- Two Phase 3 Trials (SUNRISE & SUNSHINE) met their primary endpoint: more patients treated with secukinumab achieved HiSCR compared with placebo at week 16

Casseres et al. J Am Acad Dermatol. 2020
Marasca et al. JAAD Case Rep. 2019

# Ustekinumab

- Human monoclonal antibody against IL-12 and IL-23
- Dosing: 45mg (<100kg) or 90mg (>100kg) at weeks 0, 4, then q12 weeks
- 17 patients in open-label study treated with above regimen
  - Week 40: 82% (14/17) of patients had moderate to marked improvement of the modified Sartorius score
  - 47% (8/17) achieved the Hidradenitis Suppurativa Clinical Response (HiSCR)
- 14 patients, retrospective review
  - Initial weight-based IV infusion of ustekinumab (between 260-520mg), then 90mg SC q8 weeks
  - 50% reached HiSCR at week 16; 71% had improvement of DLQI and VAS of pain

Blok et al. Br J Dermatol. 2016; Romani et al. Dermatology. 2020

# Anakinra

- IL-1 receptor antagonist
- Dosing: 100mg SC daily
- RCT with 20 patients with HS II or HS III
  - 10 received anakinra, 10 received placebo for 12 weeks
  - At week 12: HiSCR achieved in 78% (7/9) of the anakinra arm (1 patient lost to follow-up) and 30% (3/10) of placebo arm
  - Change in overall DLQI at weeks 12 and 24 from baseline at week 0 was not different between the study arms

Tzanetakou et al. JAMA Dermatol. 2016

# Other Therapeutics

- Cyclosporine (3-5mg/kg/day) has shown benefit in some reports[1,2]
- Colchicine: mixed reviews

1. Anderson et al. J Dermatolog Treat. 2016; 2. Rose et al. Clin Exp Dermatol. 2006; 3. Van der Zee et al. Dermatology. 2011; 4. Armyra et al. Int J Dermatol. 2017; Brocard et al. Dermatology. 2007

# Zinc


- Zinc gluconate 90mg PO daily
- Pilot study: 22 patients with HS (11 Hurley Stage I, 10 Hurley Stage II, 1 Hurley Stage III)
  - 8/22 (36%) had a complete remission (disappearance of cutaneous lesions or no new lesions during 6 months or more) – most were Hurley Stage I
  - 14/22 (63.6%) had partial remission (reduction of 50% or more of the number of nodules and/or a shorter cycle of each inflammatory lesion)
- Main side effect: GI distress
- Excess zinc supplementation may lead to copper deficiency

Brocard et al. Dermatology. 2007

# Complementary and Alternative Medicine

- 303 respondents, HS Specialty Clinics, international social media support groups, 16 countries
- 255 (84.2%) reported using CAM, but only 177 of these (69.4%) disclosed CAM use to HCP

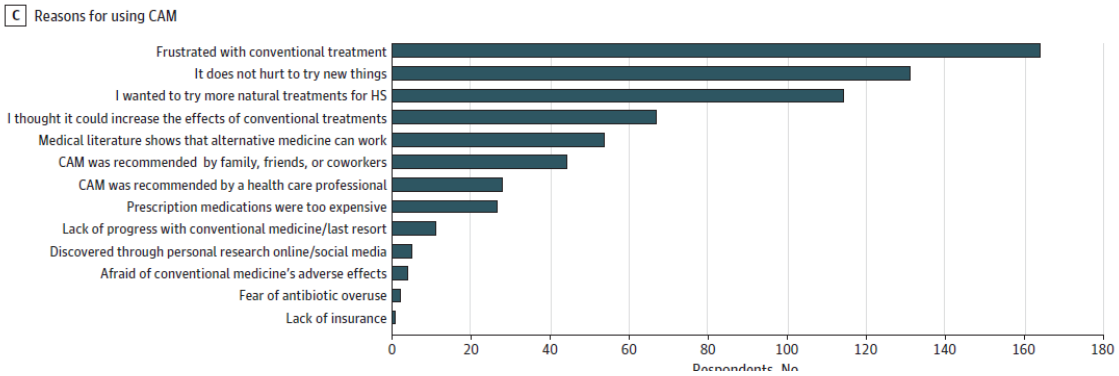


Price et al. JAMA Dermatol. 2020


Journal of Dermatological Treatment

Taylor & Francis

ISSN: 0954-6634 (Print) 1471-1753 (Online) Journal homepage: https://www.tandfonline.com/loi/ijdt20

## Non-pharmacologic approaches for hidradenitis suppurativa – a systematic review

Aleksi J. Hendricks, Penelope A. Hirt, Sahil Sekhon, Alexandra R. Vaughn, Hadar A. Lev-Tov, Jennifer L. Hsiao & Vivian Y. Shi

# Updates on Therapies

- **Guselkumab** (anti-IL-23 antibody)
  - Did not meet primary endpoint in phase 2 trial
- **Risankizumab** (anti-IL-23 antibody)
  - Phase 2 trial?

# Updates on Therapies

- **Bimekizumab** (anti-IL-17A and IL-17F)
  - Phase II trial comparing bimekizumab, adalimumab, and placebo

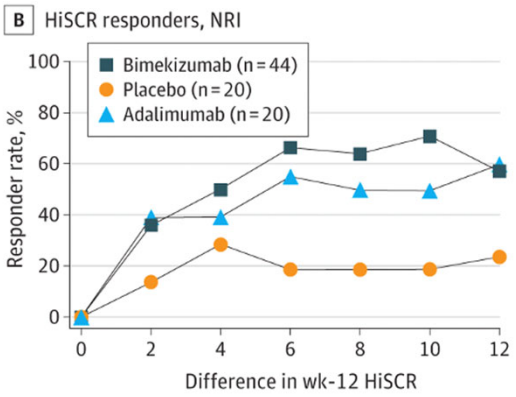


Glatt et al. JAMA Dermatol. 2021

# Updates on Therapies

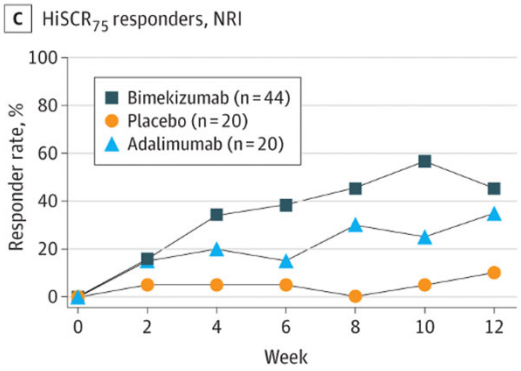


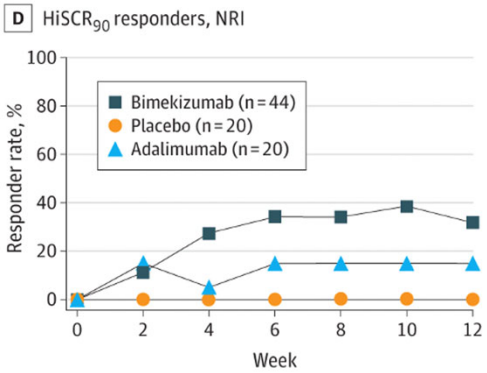


Glatt et al. JAMA Dermatol. 2021

# Emerging Therapies

Including:

- Anti-IL-1
- Anti-IL-17
- Anti-IL-36
- JAK inhibitors
- C5a inhibitor
- PDE4 inhibitor
- Anti-CD40

# Guselkumab in Patient with Multimorbidity

- 28 yo woman with Crohn's disease, HS, and psoriasis. Had tried adalimumab, secukinumab, infliximab, methotrexate, ustekinumab. Had been on doxycycline 100mg PO BID for a few months.
- Started on guselkumab for psoriasis, HS, CD:
  - 11/2018: 1st injection
  - 12/2018: 2nd injection
  - 02/2019: 3rd injection

Berman et al. J Dermatolog Treat. 2019

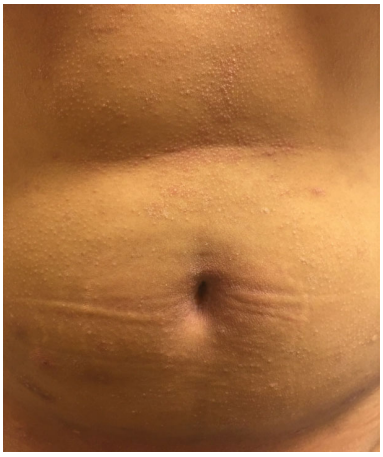

## Management of Severe HS Patients

- Biologic + oral antibiotics + either acitretin or dapsone or colchicine or other disease modifying treatment +/- hormonal agent
- If disease is very severe, consider recommending hospitalization and starting IV antibiotics + immunomodulator

## Therapies Not Supported by Literature

- Isoniazid
- Etanercept
- Intravenous immunoglobulin (IVIG)

Scheinfeld. Dermatol Online J. 2013

## Case Study

- 54 yo woman with history of PCOS, DM type 2, obesity (110kg), undifferentiated connective tissue disease, fibromyalgia, depression, anxiety, and smoking (1-2 e-cigarettes/day, formerly 1ppd cigarettes)
- 10 year history of HS: diffusely scattered open comedones, erythematous papules and nodules, and scarring in the bilateral axillae, mammary region, groin folds, on the buttocks, and under the abdominal pannus (diffuse Hurley stage II)

## Case Study

- HS Regimen:
  - Adalimumab 40mg SC weekly
  - Acitretin 25mg daily (cleared by patient's psychiatrist to start)
  - Spironolactone 100mg daily
  - Metformin ER 1000mg daily
  - Liraglutide 1.8mg SC daily
  - BP wash daily
  - Clindamycin 1% solution BID
  - ILK injections
  - After starting adalimumab, patient also took a two month course of oral clindamycin 300mg PO BID (rifampin had too many medication interactions)

# Patient’s Care Team

- Dermatologist
- Internist (PCP)
- Endocrinologist
- Rheumatologist
- Nutritionist
- General surgeon (patient s/p gastric sleeve surgery)
- Psychiatrist
- Therapist
- Acupuncturist (East West medicine)

## Case Study Take Home Points

- Combination therapies for HS may be helpful, especially in patients with recalcitrant disease or who may not be good surgical candidates
- Consider the patient's comorbidities when choosing HS therapeutics (this patient has PCOS, diabetes, obesity, and depression)

## Procedural Management

# Intralesional Steroid

- Intralesional triamcinolone (10mg/ml) helps to reduce pain and inflammation

Riis et al. J Am Acad Dermatol. 2016

# Botulinum Toxin

- A few reports note that botulinum toxin (BTX) injections have improved HS
- Consider in patients with coexisting hyperhidrosis
- Systematic review on hyperhidrosis treatments in HS:
  - BTX-A: 6/11 (55%) patients improved
  - BTX-B: RCT of 20 HS patients showed significant reduction in total lesions from baseline at 3 and 6 months compared to placebo group.

- Of note: Microwave-based energy devices may be harmful - an RCT was discontinued due to worsening HS in 5 of 8 patients

Campanati et al. Dermatol Ther. 2019
Shih et al. Dermatol Ther. 2021

# Laser Therapy

- Laser hair removal (1064-nm Nd:YAG laser, 800-nm diode laser, non-Q-switched ruby laser)
- Laser treatment of active lesions
- Photodynamic therapy
  - Intralesional photodynamic therapy: intralesional photosensitizer (5-aminolevulinic acid 5% gel or 1% solution) administered into sinus tracts and nodules, and then after incubation period, a 630-nm laser introduced into the lesion through a fiber optic probe
- CO2 laser surgery (tissue debulking)

Hamzavi et al. J Am Acad Dermatol. 2015
Suarez Valladares et al. J Dermatol Sci. 2017

# Wide Local Excision

- Retrospective study of 74 patients with Hurley stage III HS who underwent wide local excision and secondary intention healing
  - DLQI scores went from 27.89 to 5.31 after surgery
  - 70.3% of patients were satisfied with the cosmetic results.
- 84 patients (most with Hurley stage II or III) who underwent wide local excision and secondary intention healing, answered questionnaire
  - Recurrence in 37.6% of the procedures within a mean follow-up period of 3 years
  - Total remission of an anatomical area achieved in 49% of procedures
  - 92% of patients were glad they had the operation

Posch et al. J Am Acad Dermatol. 2017
Deckers et al. J Eur Acad Dermatol Venereol. 2017

# 40 yo woman with Hurley stage III (R axilla)

- Good candidate for surgery
  - Localized disease
  - Refractory disease
  - Sinus tracts and scarring
  - Deep inflammatory nodules



Photos courtesy of Dr. Richard Bennett


# SHARPS study

- RCT: 206 patients randomized to receive either adalimumab (40mg) or placebo during pre-, peri-, and post-operative weeks of surgery.
- At week 12, significantly more patients receiving adalimumab vs placebo (48% v 34%, p=.049) achieved HS clinical response across all body regions.
- No increased risk of postoperative wound infection, complication, or hemorrhage was observed with adalimumab vs placebo.

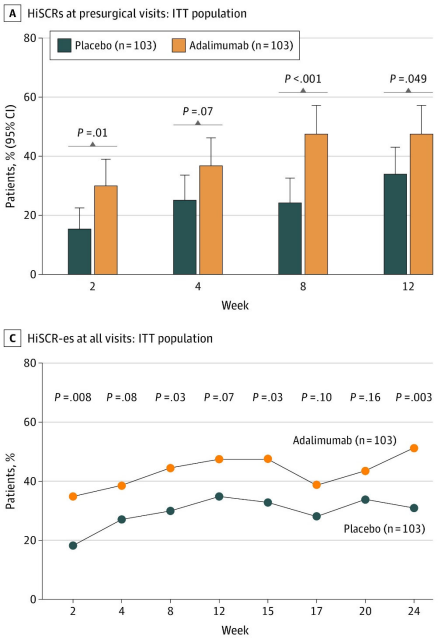


Bechara et al, JAMA Surgery 2021

# Management Tips

- Female patient with papular Hurley Stage 1 disease who reports consistent flare of HS with menses: consider OCP +/- spironolactone
- Patient who is obese or has PCOS: consider metformin
- Patient with severe localized HS with drainage: start systemic antibiotics to help decrease disease activity and then surgically excise
- Patient with severe HS (who is not a good surgical candidate) and who has failed antibiotics, adalimumab, infliximab: consider other biologic like secukinumab, ustekinumab, anakinra, IL-23 inhibitor as well as medication stacking


Shih et al. Cutis. 2021

# HS Comorbidities

- **Cardiovascular**: obesity, diabetes type 2, dyslipidemia, hypertension, metabolic syndrome, smoking, obstructive sleep apnea
- **Inflammatory disease**: acne, follicular occlusion tetrad, pyoderma gangrenosum, inflammatory bowel disease, arthritis
- **Hormonal**: polycystic ovary syndrome
- **Psychological**: anxiety, depression, decreased work productivity, social isolation, impaired sexual health, substance use disorder

Garg et al. J Am Acad Dermatol. 2021

# HS Complications

- Cutaneous complications
  - Anal, urethral, and rectal strictures and fistulas
  - Lymphedema
  - Contractures and limb mobility limitations
  - Cutaneous squamous cell carcinoma
- Systemic complications
  - Anemia
  - Systemic amyloidosis
  - Serious infection

Alikhan et al. J Am Acad Dermatol. 2009

## Multidisciplinary Approach

- Dermatology
- Primary care
- Obstetrics/Gynecology
- Plastic surgery
- General surgery
- Urology
- Gastroenterology
- Nutrition
- Bariatric surgery
- Endocrinology
- Cardiology
- Rheumatology
- Infectious Disease
- Psychiatry
- Psychology
- Pain management

## Thank you!

- Questions? Please e-mail me at:
  Jennifer.Hsiao@med.usc.edu
- Special thank you to our HS patients and my research fellows Terri Shih and Justine Seivright
- HS Foundation: Our vision is to live in a world where no one suffers from HS